

HISTORICAL NOTE

Sigmund Freud's oral cancer

Nicholas Lazaridis

Professor, Department of Oral and Maxillofacial Surgery, G. Papanikolaou General Hospital, Aristotle University of Thessaloniki, Thessaloniki, Greece

INTRODUCTION

In May 1999 members of the West Kent Medico-Chirurgical Society visited the city of Thessaloniki, in Greece. As part of the activities, we organised a scientific meeting about historical medical subjects. It was suggested, that I, an Oral and Maxillofacial Surgeon, should speak to our English colleagues about Sigmund Freud's oral cancer. Many of those who attended the meeting wanted to see the publication of Freud's illness, which has elements of a great classical epic (comical at times, but always courageous and tragic).

SMOKING

Sigmund Freud (1856–1939) (Fig. 1), the father of psychoanalysis, loved cigars.^{1,9} At age of 72, Freud wrote about his eventually fatal habit: "I began smoking at the age of 24, first cigarettes but soon exclusively cigars, and am still smoking now and very reluctant to restrict myself in this pleasure . . .".² In 1923 he was 66 years old and he smoked up to 20 cigars a day. In most of his portraits, Freud is shown with his beloved cigar, the Don Pedro, his favorite brand. In 1889 when he was 33, Freud had a cardiac incident and arrhythmia. His physician, Wilhelm Fleiss, advised him to reduce his smoking and eventually stop altogether, advice that Freud ignored saying: "I am not obeying your smoking prohibitions; do you really consider it such a boon to live a great many years in misery? Smoking has rendered me such service during my life that I can only be thankful. Without it I could not have worked as hard or long as I did".³ Freud's habit eventually caused oral cancer that tortured him for 16 years and eventually proved fatal.

Freud became aware of a painful swelling in his palate in the autumn of 1917 without, however, giving it much attention. In his opinion, the cause of the swelling was that for a short time he was forced to stop smoking, as cigars had become scarce toward the end of World War I. The swelling disappeared, as he thought, when he took

up smoking again. He even concluded that the lesion was psychogenic. Up until February 1923 the cancer did not particularly bother him. It was then, however, that the lesion became ulcerated. Once again Freud procrastinated for about 2 months, until April of the same year, when (aged 67) he visited Maxim Steiner, a dermatologist and friend, and Felix Deutsch, his family physician and also a friend. He said to Deutsch: "be prepared to see something you will not like".³ Both his doctors came to the same clinical diagnosis of advanced cancer developing in the right posterior hard palate. As they were both aware, however, that Freud also suffered from angina and depression because of the death of his grandson, they informed him that his cancer was only 'a bad case of leucoplakia due to excessive smoking, which requires a biopsy and removal of the diseased mucous membrane by operation'.³ Nevertheless, Freud suspected that the lesion was cancer and referred to it as "my dear neoplasm".⁴ He even felt betrayed by his doctors' deception and avoided Deutsch for months. He preferred, on his own initiative, to ask the opinion of Markus Hajek, Professor of Laryngology at the University of Vienna, who advised operation. So began a disastrous chapter in the treatment of Freud's cancer.⁴ Freud was rather doubtful of Hajek, despite the latter's reputation as the best otolaryngologist in Vienna. He felt that Hajek was rather ambivalent towards his patients,¹ an intuition that was soon justified. Concerning Hajek's surgical skills, Schur² noted in Freud's memoirs, 'Freud: living and dying', that Hajek was a mediocre surgeon. Schur's most important note in these memoirs was that Hajek was not qualified to operate on a malignancy that would involve the resection of the maxilla.

Hajek (1861–1941) (Fig. 2) was the son of a peddler who lived in a small town, in Hungary. He studied medicine at the University of Vienna and specialized in rhinology and laryngology. His career was somewhat erratic and he was often in conflict with the head of his department, Professor Schroetter, as the latter refused to grant Hajek a permanent appointment, at least as long as he (Schroetter) was alive. Hajek's reply to that was: "then professor it would be dishonest of me to wish you a very




Fig. 1 Sigmund Freud with his daughter Anna before the treatment of his oral cancer (redrawn from Bourgeron⁹).



Fig. 2 Marcus Hajek (redrawn from Davenport⁴).

long life". This hitch in Hajek's career was only temporary, as he went on to marry the daughter of Professor Schnitzler, founder of the Vienna nose and throat clinic. As a result of his marriage, Hajek's career bloomed, since his most important hindrance (Professor Schroetter) was also put aside. Hajek eventually became chief of the Rhinological Hospital of the University of Vienna and used the term 'Hajek's triad', to describe aspects of nasal septal perforation as mucosal dryness, septal deviation, and infection.

FREUD'S FIRST OPERATION

On April 20, 1923, Deutsch accompanied Freud to the private outpatient clinic run by Hajek and the lesion was excised as an outpatient procedure. The operation was botch. Hajek neglected to establish whether his surgical margins were free of tumor, nor did he achieve adequate hemostasis.^{1,3} The tumor was only partly removed and severe bleeding during the operation meant that Freud could not return to his home as planned, but would have to be admitted to Hajek's hospital. Unfortunately the hospital was full and Freud was forced to spend the night in a tiny room in Hajek's clinic, shared with a mentally retarded, deaf-mute dwarf. During the night, another severe hemorrhage occurred and Freud, unable to speak, could not ask for help.^{1,4} His courageous roommate, however, scoured the hospital for assistance and eventually managed to find a nurse who controlled the bleeding. When Freud's daughter, Anna, arrived at Hajek's clinic she found her father dazed, sitting on a chair, covered in blood, without a doctor or nurse in attendance. Anna refused to leave her father and stayed with him all through the night. Another yet incredible fact was that when a little later Freud's condition deteriorated alarmingly, the clinic's overnight house surgeon refused to get out of bed and treat Freud. Hajek did his rounds next morning but he paid very little attention to Freud's condition other than presenting the details to his accompanying students. Then he went on to discharge Freud from the hospital.

Jacob Erdheim, Professor of Pathology, diagnosed 'squamous cell carcinoma', a diagnosis that Freud had made for himself when he referred to his lesion as "my dear neoplasm". Hajek advised radiotherapy, which was carried out by Guido Holzknacht. One of Hajek's assistants, Feuchtinger also gave Freud a series of radium capsule treatments.^{4,5} Radiotherapy interfered with scar contracture, causing Freud pain and trismus.

On September 23, 1923, Deutsch arranged for Freud to see another surgeon, Professor Hans Pichler (Fig. 3). Pichler found a crater-shaped ulcer on the posterior aspect of the right maxillary tuberosity, a palpable submandibular node and trismus. He planned a 'partial resection of the right maxilla coupled with resection of the lingual cortex




Fig. 3 Hans Pichler, MD, DDS (1887–1949) (redrawn from Wolfe and Berkowitz⁶).

of the right mandible from the coronoid process to the lower first right molar'.¹ Pichler planned Freud's operation with great care and practiced on cadavers to perfect the technique. His approach was influenced by Claude Martin who, already since 1889, had stressed the importance of immediate prosthetic obturation for patients after maxillectomy. Pichler's preparations consisted of rigorous oral hygiene, replacing defective restorations, fitting inlays with provision for obturator retention and fabricating removable partial dentures to restore the defect caused by the ablative surgery.

PICHLER

Hans Pichler (1877–1949) was the son of a renowned dentist who looked after the Austrian court. He was an excellent student. He studied medicine in Vienna, Freiberg, and Prague. After a year of training in general surgery, in Vienna, he abandoned his aim to specialize in surgery, as he had developed eczema from the carbolic acid spray used by surgeons at the time. He therefore switched to dentistry and in 1902 he began his studies under the supervision of "the father of modern dentistry", GV Black, at the Northwestern University school of Dentistry, in Chicago. Black was the first American to maintain reduction of

fractures of the jaw by circumferential wiring. As soon as Pichler returned to Vienna, he took up an academic career and became a productive writer. Listed among his works is his book: "Surgery of the Mouth and Jaws". As a person, Pichler kept a low profile. He was an excellent oral surgeon and his technique was aggressive for his times. It was he who started using prosthetic replacements. His assistant, Otto Hofer, was the first to describe a genioplasty. Pichler also trained Richard Trauner, who in turn trained Hugo Obwegeser, who has now trained more maxillofacial surgeons than anyone.⁶

FREUD'S SECOND OPERATION

The operation was carried out in two stages, on October 4 and 11, 1923. In the first stage, Pichler ligated the right external carotid artery to reduce hemorrhage during the second stage and removed the submandibular gland and lymph nodes. This stage was done under local anesthesia with pantopon (an opium derivative) sedation. Histologic examination of the specimen failed to identify any sign of malignancy. Local anesthesia was preferred to general anesthetic because the risk of inhalation of blood was reduced. In the second operation (October 11, 1923) Pichler used electrocautery. His extraoral incision extended from the midline of the upper lip, around the alar base, halfway up the side of the nose. He removed part of the right maxilla, from the canine, to the tuberosity, and part of the lower jaw (medial aspect of the coronoid, lingual aspect of the ramus and the lower right first, second and third molars with adjacent bone). Raw areas of the right cheek were grafted with split thickness skin graft from the upper arm. The maxillectomy cavity was then packed with iodiform gauze and the prosthesis fashioned by Pichler was inserted. After the operation, Pichler was of the opinion that his only mistake was that he hadn't removed more medial pterygoid muscle, and he was afraid that there would be a recurrence in that area. The pack was replaced after a week. Three weeks later, Pichler noted (on November 7) a small ulcer in the area of the right process. It was a recurrence confirmed by biopsy as malignant.

FREUD'S THIRD OPERATION

The third operation was carried out by Pichler on November 12. This involved the removal of the remaining right pterygoid process and most of the right side of the soft palate, although he left a posterior margin of about 1 cm wide. Shortly afterwards, however, the soft palate broke down completely and so Freud was left with a maxillary defect which presented considerable difficulties in achieving effective prosthetic obturation.⁵ As a result, eating, speaking, smoking and achieving stability and comfort of

the obturator remained huge problems for Freud for the rest of his life. These problems aggravated with the appearance of severe trismus.

FREUD'S FOURTH OPERATION

On November 17, 1923, Freud decided to undergo the Steinach operation by Victor Blum. This operation included the ligation of the vas deferents, supposedly to stimulate the secretion of the testicular hormone and hopefully rejuvenate the patient. As cancer was considered a disease most likely to affect old people, this rejuvenation was expected to affect Freud's cancer in a positive way. However, Freud himself stated that this certain operation did not ameliorate his condition, even though he had no further recurrence until 1936.

THE OBTURATOR PROSTHESIS

The obturator prosthesis, initially fabricated by Pichler, separated Freud's oral and nasal cavities. It was a combination of obturator and removable partial denture constructed of vulcanite, a type of hard rubber and gold. The artificial teeth were made of porcelain. Freud named the device "the monster" and described as he mentions: "the very model of a necessary evil".⁷ As the shape of a maxillectomy cavity changes constantly, particularly during the early stages of the oral mucosa healing, numerous alterations and realignment with gutta percha and wax were made by Pichler. All the extensions of the obturator, or 'clod', were moulded in Freud's mouth and when the re-application was considered successful, they were reproduced in vulcanite.^{1,4,5}

However, despite the constant adjustments of the prostheses (five by 1928), Freud, even though he was grateful to Pichler, continued to have great difficulties with them, including pain and inefficient obturation. Insertion of the obturator could be achieved only with the help of his daughter Anna (Fig. 1). Despite the improvements that Pichler effected, which made the obturator more secure, Freud was not satisfied and in his despair he turned to an expert in prosthetics, Professor Hermann Schroeder of the Dental Institute of the University of Berlin. Schroeder undertook the creation of a new prosthesis in Berlin, which was an improved version of the previous ones in terms of comfort and function. When Freud returned to Vienna, Dr Joseph Weinmann, a student of Schroeder's, undertook the care of this new prosthesis. Pichler, however, was still Freud's surgeon.^{4,5} Weinmann later became professor of dentistry in Chicago.

There is no doubt that the new dentures were much better than the previous ones. Pichler was impressed when he saw them, even though he was worried that the failure



Fig. 4 Varastad H. Kazanjian, MD, DDS (1879–1974) (redrawn from Wolfe and Berkowitz⁶).

of the bridge through loosening of the 'pillars' or abutment teeth could destroy this good result.

For 3 years Freud had no particular problems with his new dentures, until 1931 when he once again thought that he needed a new denture. At that time, two of his friends, Ruth Mack Brunswick and princess Marie Bonaparte, one of Napoleon's descendants, persuaded a rather reluctant professor Varastad Kazanjian (Fig. 4), an oral and plastic surgeon who was in Berlin on a visit from the United States, to treat Freud. During World War I Kazanjian had worked in Britain with Harold Gillies and treated British soldiers with facial wounds. He then returned to the States, studied medicine, and evolved into an excellent plastic surgeon. The American press referred to him as "the miracle man of the western front". Brunswick tracked Kazanjian to his hotel in Berlin, while he attended a dental conference.¹ At first Kazanjian refused to undertake the making of a new prosthesis. Brunswick, however, persuaded her father (a member of the board of overseers at Harvard) to intervene and convince Kazanjian to treat Freud.

Kazanjian worked in Pichler's practice and in 3 weeks' time he made a new denture for Freud (Fig. 5). He was paid \$6000 for his work. That prosthesis was only half as big and heavy as the previous one. Despite its high cost, it was not particularly successful. Freud, however, used it for 3 years until 1934. He was impressed with Kazanjian's

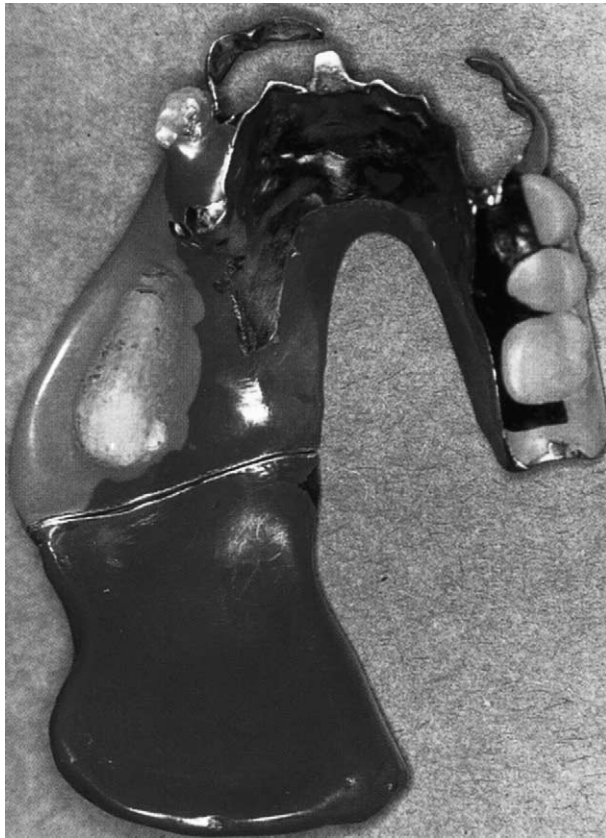

Fig. 5 Freud's prosthesis provided by Kajanjian in 1931 (redrawn from Davenport⁴).

personality, referred to him as "the magician", and described him as "a shy man with a smile like Charlie Chaplin".⁷ He stated about Kazanjian's prosthesis: "I can speak, chew and smoke at least as well as before".

In 1934, a premalignant lesion appeared that required radiotherapy, which was given through a new vulcanite prosthesis supplied by Pichler.⁴ Shortly afterwards, Pichler replaced this radium prosthesis using a duplication technique.

In 1936, Pichler diagnosed a recurrence of Freud's cancer, the first one since 1923. A new operation followed, which was the first one for which Freud was given a general anesthetic and not surprisingly he stated that he was greatly impressed by the procedure.

That same year, the Nazis came in Vienna. And even though Freud proclaimed himself an atheist, he was, nevertheless, raised in the Jewish faith and was a member of the Viennese Jewish Society. The Gestapo threatened to arrest him and his family members on many charges, so he seriously considered fleeing to London. He used to say, however: "Where should I go in my state of dependence and physical helplessness".⁷ He obviously felt secure to be near his surgeon, Pichler, who, even when off duty, would not go far from his patient. However, the tempo-



Fig. 6 Freud's home from 1938 to 1939, now the Freud Museum (redrawn from Davenport⁴).

rary arrest of Freud's daughter, Anna, by the Gestapo convinced Freud to flee to London. Pichler, whose influence at that time had grown greatly in Austria, helped him to escape. Freud's son, Ernst, was already living in London, so Freud emigrated there with Anna. He was accompanied by his doctor and friend, Schur. They moved into a house in Swiss Cottage, which is now the Freud museum (Fig. 6).

On Pichler's recommendation, Freud (Fig. 7) entrusted his care in London to George Exner, a brilliant oral surgeon. He was also kept under observation by Trotter, a general surgeon, and Harmer, an ENT surgeon. However, when a new recurrence appeared Pichler had to travel to England and be at the London clinic to operate on Freud for the last time in September 1938.⁸

A year later, in September 1939, Dr Finzi advised radiotherapy. Until his death on September 23, 1939 had been a difficult year for Freud. His terrible pain was relieved with Orthoform, a distant relative of cocaine. The painkiller was applied directly on to his mouth. His deterioration was inexorable and during a period of few months the skin over the right zygoma became gangrenous; eventually there was a perforation between the oral cavity and the skin. His friend and doctor, Shur, when he became aware of the through-and-through defect, thought about using this route for the topical anesthetic. However, the smell from the necrotic tissue was appalling and Freud was particularly distressed when his pet dog, Chow, unable to stand the unpleasant smell, would sit in the corner of Freud's room. Freud's bed was covered with mosquito netting because flies were attracted to this odor.¹ As months went by even Orthoform provided little relief from the pain, and Anna and Doctor Shur could see that the end was near.




Fig. 7 Passport photo of Freud in 1938. The postoperative asymmetry of his face is noticeable on the right side (redrawn from Aziz¹).

Up to then, Freud continued to see several patients a day but he finally decided he could work no more. Some time in 1928 Freud had made doctor Shur promise him that he wouldn't let him suffer unreasonably at the end of his life. So on September 21, 1939, Freud sought help from Maxim Shur and asked him to keep his earlier promise. Freud grasped Shur's hand and whispered to him: "My dear Shur, you certainly remember our first talk. You promised me then not to forsake me when my time comes. Now it is nothing but torture and makes no sense any more".² Shur gave him 200 mg of morphine and 200 more after 12 hours. Freud slipped into a coma and died at 3:00 a.m. on September 23, 1939, at the age of 83. That's how his brilliant but turbulent life came to an end, with euthanasia.⁸

During his 16-year-long health trial, although a number of specialists subsequently made occasional contribution to Freud's treatment the 'team' responsible for most of his care from 1917 until his death in 1939 consisted essentially of one man, Professor Hans Pichler.⁴

This great man and maxillofacial surgeon did all the necessary operations (33 procedures in all) and made most of the prostheses required for rehabilitation. For 16 subsequent years, he provided care and support during Freud's illness. This meant a great commitment as it required numerous and frequent appointments. In 1924 alone 74 appointments were needed. A graphic representation of this period was done in German by Pichler himself, but in an obscure form of shorthand invented by his father. The only other person who understood the shorthand writing was Pichler's secretary, who copied all the notes in clear handwriting in the German language. The translation into English was done by Dr Lagos Levy and the accuracy of the translation was revised by Dr Maxim Shur, Freud's faithful friend and physician. The Freud museum at 20, Maresfield Gardens, Swiss Cottage, London was Sigmund Freud's home for the last year of his life from 1938 to 1939.

REFERENCES

1. Aziz SR. Sigmund Freud: psychoanalysis, cigars, and oral cancer. *J Oral Maxillofac Surg* 2000; 58: 320–323.
2. Schur M. Freud: Living and Dying. New York: International Universities Press, 1972.
3. Deutsch F. Reflections on Freud's one hundredth birthday. *Psychosom Med* 1956; 18: 280–283.
4. Davenport JC. Sigmund Freud's illness: the ultimate team approach to head and neck cancer? *Facial Plast Surg* 1993; 9: 125–132.
5. Davenport JC. The prosthetic care of Sigmund Freud. *Br Dent J* 1992; 172: 205–207.
6. Wolfe SA, Berkowitz S. Plastic Surgery of the Facial Skeleton. Boston: Little, Brown, 1989: 10.
7. Freud S. The Diary of Sigmund Freud 1929–1939. New York: MacMillan, 1992.
8. Romm S. The unwelcome intruder. Freud's Struggle With Cancer. New York: Praeger Publishers, 1983.
9. Bourgeron J. Freud: secrets of his family. *Illustrated Greek Hist* 2000; 389: 111–114.

The Authors

Nicholas Lazaridis

Professor
Department of Oral and Maxillofacial Surgery
G. Papanikolaou General Hospital
Aristotle University of Thessaloniki
Thessaloniki, Greece

Correspondence and requests for offprints to: Professor Nicholas Lazaridis, Department of Oral and Maxillofacial Surgery, G. Papanikolaou General Hospital, Aristotle University of Thessaloniki, Thessaloniki, Greece.
Tel: +30 31 244 177/0932413337 (M); Fax: +30 31 999 451.

Accepted 18 November 2002